

Original Research Article

A STUDY OF HISTOPATHOLOGICAL PATTERNS OF BREAST LESIONS IN A TERTIARY CARE CENTRE

Ammatul Mugni¹, Sunita Nyamagoudar², Ramesh B H³, Ankitha Patil⁴, Ramya T⁵

^{1,5}Assistant Professor, Department of Pathology, Ashwini Rural Medical College, Hospital and Research Centre, Kumbhari, Solapur, Maharashtra, India.

^{2,4}Assistant Professor, Department of Pathology, Raichur Institute of Medical Sciences, Raichur, Karnataka, India.

³Professor and HOD, Department of Pathology, Raichur Institute of Medical Sciences, Raichur, Karnataka, India.

Received : 10/10/2024
Received in revised form : 25/11/2024
Accepted : 09/12/2024

Corresponding Author:

Dr. Ankitha Patil,
Assistant Professor, Department of Pathology, Raichur Institute of Medical Sciences, Raichur, Karnataka, India.
Email: ankitharaichur@gmail.com

DOI: 10.70034/ijmedph.2024.4.187

Source of Support: Nil,
Conflict of Interest: None declared

Int J Med Pub Health
2024; 14 (4); 1014-1020

ABSTRACT

Background: Breast Carcinoma is one of the most common neoplasms in females. In India, it is the second most common cancer after cervical cancer. Most of the breast lesions usually present as a lump in the breast. Screening and early diagnosis of different neoplastic and non-neoplastic breast lesions is important for prompt intervention.

Materials and Methods: This is retrospective study done in the department of pathology, in a tertiary care centre. A total of 154 cases of breast lesions were classified as neoplastic and non-neoplastic lesions. The neoplastic lesions were classified based on WHO classification of tumors of the breast.

Results: Out of 154 cases, 152 cases (98.70%) were female. The peak age of the occurrence of the breast lesions was seen in the age group of 21-30 years (29.87%). The most common clinical presentation was breast lump 94 cases (61.03%). Right side was the predominant side noted in 76 cases (49.35%). Benign lesions were seen in the 113 cases (73.37%), out of which Fibroadenoma 79 cases (51.29%) was the most common lesion. Among the 35 cases (22.72%) of malignant lesions, 33 cases (N=33), (21.42%) were of Invasive Ductal Carcinoma (IDC). IDC of Grade II according to Nottingham grading system was the most common grade seen in 14 cases (42.42%). Axillary dissection was done in 27 cases (N=27), out of which 13 cases (48.14%) were positive for malignancy. On Immunohistochemistry, maximum cases of malignancy showed Estrogen Receptor (ER), Progesteron Receptor (PR) positivity and Human Epidermal Receptor 2 (HER2) Negativity in 12 cases (36.36%).

Conclusion: The spectrum of breast lesions with clinico-radiological-pathological correlation provides beneficial information and helps in proper diagnosis and adequate treatment. Female education for self-breast examination, screening malignancies and awareness programs should be implemented and encouraged for reduction of morbidity and mortality.

Keywords: Breast lump, Fibroadenoma, IDC, Nottingham grading system.

INTRODUCTION

The breast is a modified apocrine sweat gland, composed of both epithelial and connective tissue components,^[1] and is a site of a broad array of pathological alterations.^[2] Cancer of breast is one of the most common neoplasms in females.^[2] In India, breast cancer is the second most common cancer after cervical cancer.^[3]

Breast lesions are composed of several distinct entities with remarkably different characteristic

features.^[4] Breast lesions constitute as one of the prominent surgical pathologies encountered in a day to day clinical practice. Women of different age groups present with variable breast related complaints, clinical findings and a fear of malignancy.

Inflammatory lesions include breast abscess, granulomatous mastitis and others. Benign breast diseases are the most common cause of breast problems all over the world.^[5] Common benign lesions of the breast include fibroadenoma,

phyllodes tumor, lactating adenoma and tubular adenoma. Benign proliferative lesions include fibrocystic disease. Malignant lesions are broadly classified as invasive ductal carcinoma and invasive lobular carcinoma.^[6]

Most of the breast lesions usually present as a lump in the breast.^[7] Therefore, recognition of different neoplastic and non-neoplastic breast lesions is important for the differential diagnosis from malignant lesions and ultimately for the appropriate management of the patients with breast disease.^[8]

Aims and Objectives

1. To study the spectrum of breast lesions in relation to clinical presentation, age and gender.
2. Categorization of different non neoplastic and neoplastic cases according to the WHO classification of tumors of the breast and grading of neoplastic lesions by adopting Nottingham grading system.

MATERIALS AND METHODS

This is the retrospective study of all the breast specimens that were histologically diagnosed in Department of Pathology, Raichur Institute of Medical Science, Raichur over a period of 5 years from January 2017 to December 2021.

Specimens were received in 10% formalin and after processing and paraffin embedding, sections were cut and stained with hematoxylin and eosin stain (H&E). The histopathological features were noted and the tumors were classified using the WHO classification of tumors of the breast and were graded by adopting Nottingham grading system along with ER, PR and HER2 immunohistochemistry (IHC).

The specimens included excision biopsy, simple mastectomy and modified radical mastectomy. Tru-cut biopsy specimens were excluded.

Data was analyzed using Microsoft Excel.

RESULTS

A total of 154 breast specimens were received over a period of 5 years

Table 1 show maximum cases occurred between the age group of 21-30 years. The minimum cases were in the age group of 71-80 years. The mean age 32.45 years. [Table 1]

Table 2 shows maximum cases are seen in females than compared to males. [Table 2]

Table 3 is showing maximum lesions are on right side. [Table 3]

Table 4 shows lump is the most common clinical presentation of breast lesions, seen in 94 cases (61.03%). [Table 4]

Table 5 is showing maximum cases are benign compared to inflammatory and malignant lesions. [Table 5]

Table 6 shows Inflammatory lesions accounted for 6 cases (3.89%). Benign breast disease, were most

common lesions seen in 113 cases (73.37%). Among them, fibroadenoma (51.29%) was most common followed by fibrocystic disease (13.63%). In male, only gynaecomastia case was seen in 2 cases (1.29%). In malignant breast disease of 35 cases (22.72%), invasive ductal carcinoma was the predominant one with 33 cases (21.42%). [Table 6]

Table-7, Based on Nottingham grading system done on 33 IDC cases (100%), grade II was most common grade seen in 14 cases (42.42%). (N=33)[Table 7]

Table-8 shows IHC for Hormone receptors done on 33 IDC cases (100%), ER + in 19 cases (57.57%), PR+ in 18 cases (54.54%), HER2 + in 12 cases (36.36%). (N=33) [Table 8]

Table-9 Among 33 IDC cases , the predominant cases were showing ER+/PR+ status in 17 cases (51.51%). (N=33) [Table 9]

Table-10 IHC done on 33 IDC cases (100%), correlating ER/PR and HER2 receptors together, the most common cases showing ER+/PR+ and HER2 - was seen in 12 cases (36.36%). Triple negative cases was seen in 6 cases (18.18%).(N=33) [Table 10]

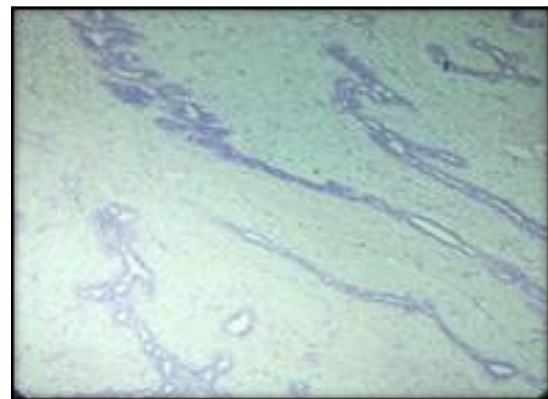


Figure 1: H&E, 10x, Fibroadenoma

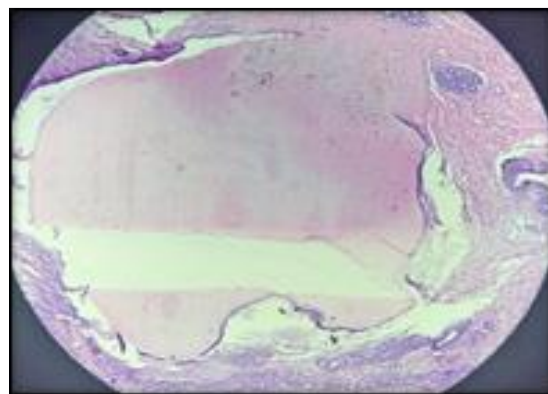


Figure 2: H&E, 10x, Fibrocystic disease

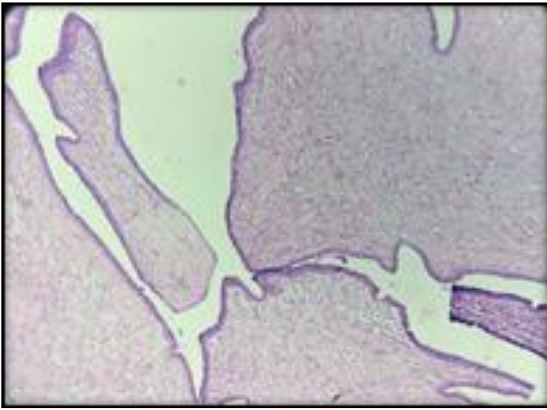


Figure 3: H&E, 10x, Benign Phyllodes

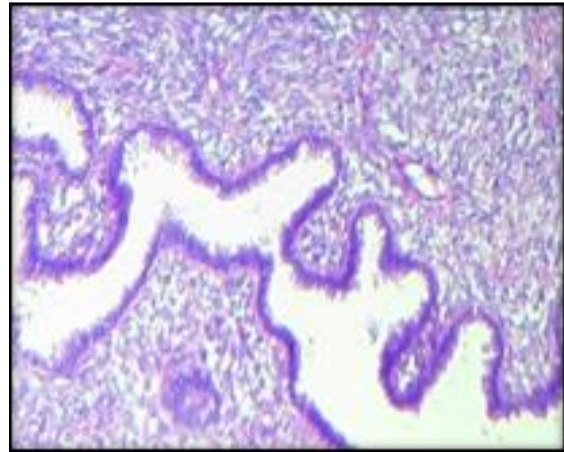


Figure 5b: H&E, 40x, Malignant Phyllodes

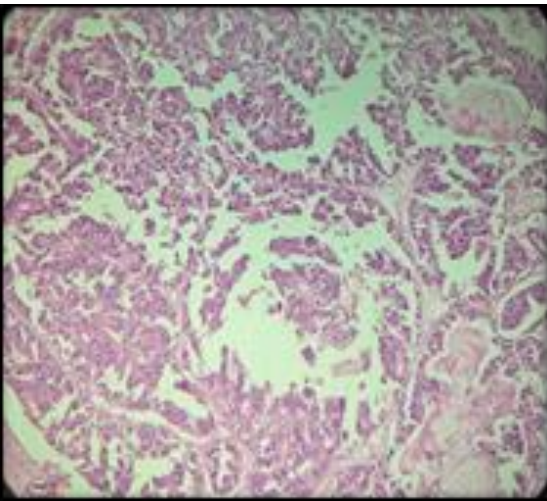


Figure 4: H&E, 10x, Encapsulated Papillary carcinoma

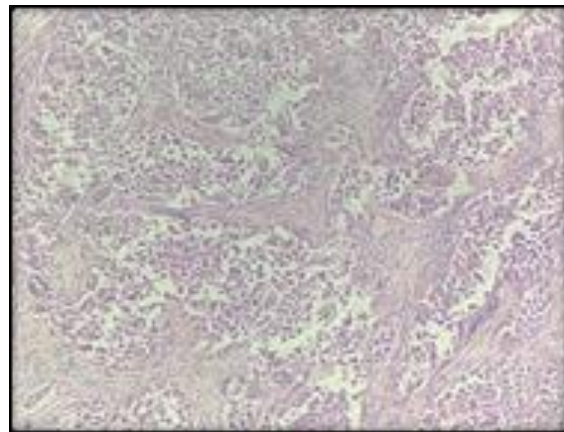


Figure 6a: H&E, 10x, Invasive Ductal Carcinoma (NOS)

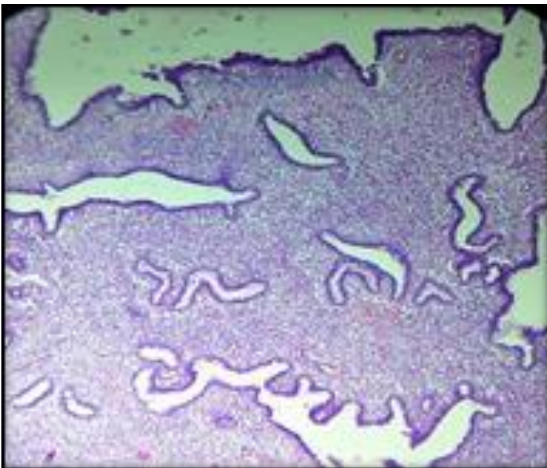


Figure 5a: H&E, 10x, Malignant Phyllodes

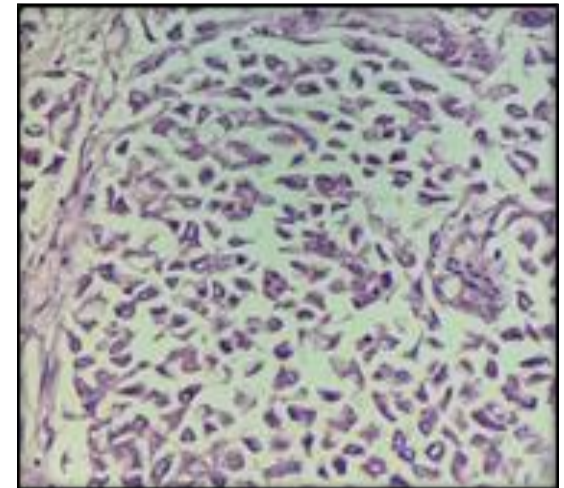


Figure 6b: H&E, 40x, Invasive Ductal Carcinoma (NOS)

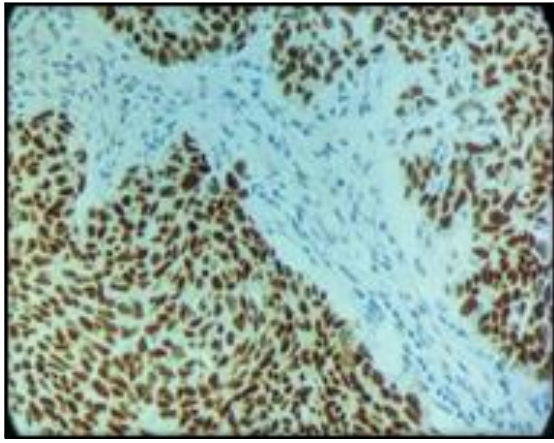


Figure 7: IHC, showing ER positivity

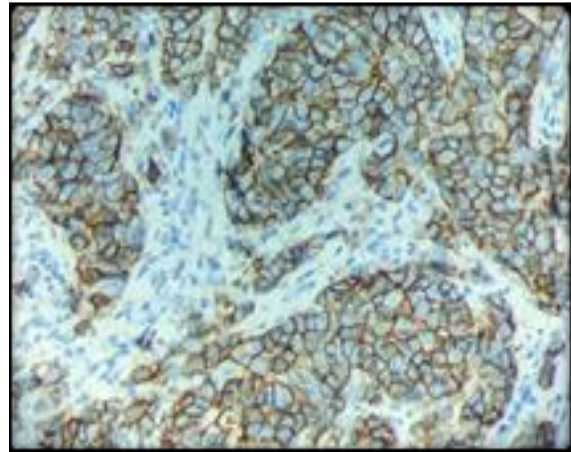


Figure 9: IHC, showing HER2 positivity

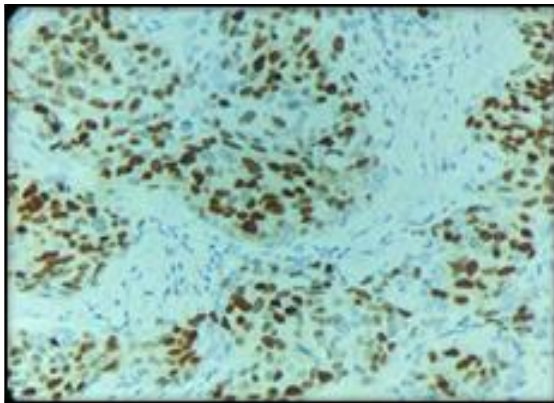


Figure 8: IHC, showing PR positivity

Table 1: Distribution of cases according to age

Age(yrs)	No. of cases	Percentage
11-20	42	27.27%
21-30	46	29.87%
31-40	27	17.53%
41-50	23	14.93%
51-60	08	5.19%
61-70	05	3.24%
71-80	03	1.94%
Total	154	100%

Table 2: Distribution of cases according to gender

Gender	No. of cases	Percentage
Female	152	98.70%
Male	02	1.29%
Total	154	100%

Table 3: Distribution of cases based on side of lesion

Side of the lesion	Total no. of cases	Percentage
Left	73	47.40%
Right	76	49.35%
Bilateral	05	3.24%
Total	154	100%

Table 4: Distribution of cases based on clinical presentation

Clinical presentation	No. of cases	Percentage
Lump only	94	61.03%
Lump with nipple discharge	18	11.68%
Lump with mastalgia	17	11.03%
Mastalgia only	13	8.44%
Peau d'orange	12	7.79%
Total	154	100%

Table 5: Distribution of cases according to lesions

Breast lesion	No. of cases	Percentage
Inflammatory	06	3.89%
Benign breast lesion	113	73.37%
Malignant breast lesion	35	22.72%
Total	154	100%

Table 6: Histological diagnosis and characteristics of breast lesions

Category	Diagnosis	No. of cases	Percentage
Inflammatory	Acute / Chronic mastitis	06	3.89%
Benign lesions	Fibroadenoma	79	51.29%
	Fibrocystic disease	21	13.63%
	Ductal hyperplasia	02	1.29%
	Atypical Ductal hyperplasia	01	0.64%
	Tubular Adenoma	01	0.64%
	Sclerosing Adenosis	01	0.64%
	Benign phyllodes	04	2.59%
	Galactocele	01	0.64%
	Lipoma	01	0.64%
	Gynaecomastia	02	1.29%
Malignant lesions	Invasive ductal carcinoma	33	21.42%
	Malignant phyllodes	01	0.64%
	Encapsulated papillary carcinoma	01	0.64%
Total		154	100%

Table 7: Showing Nottingham grading of Invasive Ductal Carcinomas (N=33)

Nottingham grading of Invasive ductal carcinoma	Grade	No. of cases	Percentage
	Grade I	11	33.33%
	Grade II	14	42.42%
	Grade III	08	24.24%
Total		33	100%

Table 8: Hormone receptors status of IDC breast cancer patients (N=33)

Hormone Receptor	Positivity Status	Frequency	Percentage
ER (N=33)	Positive	19	57.57%
	Negative	14	42.42%
PR (N=33)	Positive	18	54.54%
	Negative	15	45.45%
HER2 (N=33)	Positive	12	36.36%
	Negative	21	63.63%

Table 9: Results of ER/PR receptors status among IDC breast cancer patients (N=33)

Hormone Receptor positivity Status	Frequency	Percentage
ER Positive and PR Positive	17	51.51%
ER Positive and PR Negative	2	6.06%
ER Negative and PR Positive	1	3.03%
ER Negative and PR Negative	13	39.39%
Total	33	100%

Table 10: On IHC, Correlation of ER, PR, HER2 Receptor among IDC breast cancer patients (N=33)

Hormone Receptor positivity Status	Frequency	Percentage
ER Positive, PR Positive and HER2 Positive	5	15.15%
ER Positive, PR Negative and HER2 Negative	2	6.06%
ER Negative, PR Positive and HER2 Negative	1	3.03%
ER Negative, PR Negative and HER2 Positive	7	21.21%
ER Negative, PR Negative and HER2 Negative (Triple negative)	6	18.18%
ER Positive, PR Positive and HER2 Negative	12	36.36%
Total	33	100%

DISCUSSION

A breast lump is the most common reason for seeking surgical consultation as it is associated with heightened anxiety due to increased awareness of breast cancer in the general population.^[9] The risk factors for breast lesions includes nulliparity, late age at first child birth, older age, late menopause,

obesity, all these are mentioned only to highlight the fact towards excessive circulating estrogen.^[10,11]

In our study the most common age group was 21-30 years (29.87%) which is almost similar to the study conducted by Syed SA et al, 12 (27.64%) and Yogalakshmi S et al,^[11] (32%). The mean age in our study is 32.45 years which is similar to the study conducted by Padmon L et al,^[13] (33.63 years)

whereas in the western literature the mean age is 54 years.^[13]

The lesions were predominantly seen in females than compare to males, in the present study (98.7%) similar to done by Nwafor CC et al,^[14] (98.1%).

In our study maximum lesions were on right side (49.35%), whereas left side showed maximum lesions in the study conducted by Nwafor CC et al,^[14] (45.7%).

In the present study, majority of the patients presented with breast lump only (61.03%), comparable to the study conducted by Abhijit MG et al,^[15] (54.2%) and second common presentation in our study was Lump with nipple discharge (11.68%) which is similar to the study done by Mukhopadhyay A et al,^[16] (9.3%).

Benign breast lesions were the most common lesions in the present study accounting for 73.37%. The study done by Malik R et al,^[17] (73%) and Ssemmanda S et al,^[18] (68%) also showed benign breast disease the commonest. Benign breast disease is considered to be most common form of breast disease worldwide.^[19]

Inflammatory lesion of breast (mastitis) was seen in 3.89% of cases in the study which is similar to study done by Ssemmanda S et al,^[18] (3.9%) and comparable to study done by Olu eddo et al,^[20] (2%).

The most common benign lesion in the present study was fibroadenoma (51.29%) which is similar to the study done by Sangma et al,^[19] (52.74%) and Malik R et al,^[17] (55%). Fibrocystic disease was 13.63% in the present study which is less compared to the observation done by Jamal AA et al,^[21] (22%).

Benign phyllodes in general, account for 2-3% of all fibroepithelial breast diseases and has a peak incidence in perimenopausal age or can occur before 20 years of age.^[22] In our study Benign phyllodes was seen in 2.59% similar to the findings of Sulhyan KR et al,^[23] (2.63%).

Gynaecomastia is the enlargement of male breast and was observed in 1.29% in the present study which is similar to the study done by Olu eddo et al,^[20] (2%).

In our study maximum malignant breast tumors were seen in 4th decade followed by 6th and 5th decade. Sulhyan KR et al,^[23] found maximum incidence in 6th decade followed by 7th and 4th decade and Mudholkar VG et al,^[24] in 6th decade followed by 5th and 7th decade.

Invasive ductal carcinoma, Not otherwise specified (IDC-NOS) is the most common malignancy of the breast in our study (21.42%) which is similar to the study done by Syed SA et al,^[12] (19.97%).

IDC-NOS tumors were graded according to Nottingham grading system. In the present study Grade II is the most common grade (42.42%) and the study done by Lee et al,^[25] (40%) and Vegt et al,^[26] (45.3%) also showed similar results.

Axillary dissection was done in 27 cases (N=27, 100%) out of which 13 cases (48.14%) were

positive for malignancy in the present study, which is comparable to the study done by Yagalakshmi S et al,^[11] (47%).

Average size of tumor mass in the present study was 4.3 cms, which is slightly lesser when compared to the study done by Nwafor CC et al,^[14] (6.2cms).

The prognosis of breast cancer depends on several factors including ER, PR and HER2 status. ER positive tumors are having better overall survival compared to ER negative tumors. Therefore, evaluation of hormonal receptor status is necessary for every breast cancer case.^[27]

In the present study 19 cases (57.57%) were ER positive and 18 cases (54.54%) were PR positive, which is comparable to the study done by Shashikumar HB et al.^[28] The average ER positivity for white women in United States is 77%. Prevalance of hormone receptor positive breast cancer in Asian countries has been found to be lower than the western countries.^[28]

Triple negative were 6 cases (18.18%) in the present study, which is slightly on lower side when compared to the study done by Patnayak R et al,^[29] (22.7%).

Breast lesions commonly occur in the 3rd decade, so all women in this age group should undergo routine screening by breast examination and mammogram for the early diagnosis and timely intervention so that the prognosis of the patient becomes better.

CONCLUSION

This study highlights the significance of identifying the breast lesions by correlating the clinical, radiological and histopathological diagnosis and also classifying them according to WHO classification of tumors of the breast. Immunohistochemistry for hormonal receptors (ER, PR and HER2) aids in proper management of the patient.

Awareness and screening programs regarding the breast lump helps in timely visit of the patient to the clinics which is necessary for the early diagnosis and prompt treatment for a better outcome.

REFERENCES

1. Aslam HM, Saleem S, Shaikh HA, Shahid N, Mughal A, Umah R, et al. Clinico pathological profile of patients with breast diseases. *Diagn Pathol* 2013; 8:77.
2. Lakhani S, Ellis IO, Schnitt S J, Tan P H, Van der vijver M J World Health Organization Classification of tumours of breast, Lyon, IARC press, 2012.
3. Dhillon PK, Breast Cancer Factsheet. South asia network for chronic disease. Public Health Foundation of India 2011
4. Klein S. Evaluation of palpable breast masses. *Am Fam Physician* 2005; 71:1731-8.
5. Sainsbury R. The Breast. Bailey & Love's Short Practice of Surgery. 26th Ed. Florida. CRC Press Taylor & Francis Group. 2013. pg 798-819.
6. Kumar V, Abbas A, Fausto, et al. Pathologic basis of disease: the breast. 7th edn. Philadelphia, PA:Elsevier 2017: 1119-54.

7. Ferlay J, Shin HR, Bray F, et al. Estimates of worldwide burden of cancer in 2008: GLOBOCAN 2008 Int J Cancer 2010;127(12):2893-917.
8. Sulhyan K.R, Anvikar A.R, Mujawar I.M, Tiwari H. Histopathological study of breast lesions. Int J Med Res Rev 2017;5(01):32-41.
9. Prajapati CL, Patel UA, Patel J. Breast lumps in a teaching hospital: A 5-year study. National Journal of Medical Research. 2014 Mar 31;4(01):65-7.
10. Sharkey FE, Craig Allred DC, Valente PT, et al. Andersons pathology. 10th edn. St. Louis: Mosby 1996; p. 2454-85.
11. Yogalakshmi S, Kavitha M. A study of histopathological spectrum of breast lesions. Int J Sci Stud. 2019;7(1):1-5.
12. Syed Sarfaraz Ali, Nandkishore Pehlajani, Ekansh Rai. Histopathological spectrum of breast lesions – A study done in a tertiary care hospital. MedPulse International Journal of Pathology. October 2021; 20(1): 27-30.
13. Padmom L, Sapru K, Beena D. Histopathological Spectrum of Breast Lesions--A Study Done in a Tertiary Care Hospital. Journal of Evolution of Medical and Dental Sciences. 2020 Apr 27;9(17):1412-6.
14. Nwafor CC, Udo IA. Histological characteristics of breast lesions in Uyo, Nigeria. Niger J Surg 2018; 24:76-81.
15. Abhijit MG, Anantharaman D, Bhoopal S, Ramanujan R. Benign breast diseases: experience at a teaching hospital in rural India. Int J Res Med Sci. 2013;1(2):73-78.
16. Mukhopadhyay A, Naskar S, Dey R, Basu K. Female Breast Lesions--A Five Year Study in a Tertiary Care Centre. International Journal of Anatomy, Radiology and Surgery. 2017;6(1).
17. Malik R, Bharadwaj VK. Breast lesions in young females. A 20-year study for significance and early recognition. Indian J Pathol Microbiol. 2003;46(4):559-62.
18. Ssemmanda S, Katagirya E, Bukirwa P, Alele D, Lukande R, Kalungi S. Breast diseases histologically diagnosed at a tertiary facility in Uganda (2005–2014). BMC cancer. 2018 Dec; 18:1-7.
19. Sangma MB, Panda K, Dasiah S. A clinico-pathological study on benign breast diseases. Journal of clinical and diagnostic research: JCDR. 2013 Mar;7(3):503.
20. OLU EDDO sulhan 4
21. Jamal AA. Pattern of breast diseases in a teaching hospital in Jeddah, Saudi Arabia. Saudi medical journal. 2001 Feb 1;22(2):110-3
22. Buchberger W, Strasser K, Heim K, Müller E, Schröcksnadel H. Phylloides tumor: Findings on mammography, sonography, and aspiration cytology in 10 cases. AJR Am J Roentgenol 1991; 157:715-9.
23. Sulhyan KR, Anvikar AR, Mujawar IM, Tiwari H. Histopathological study of breast lesions. Int J Med Res Rev. 2017;5(01):32-41.
24. Mudholkar VG, Mashal SN, Kawade SB. Histopathological Study of Neoplastic Lesions of Breast. Ind Med Gazette 2012. Sept:353-64
25. Lee (sulhan 17)
26. Vegt (sulhan19)
27. Njeze G E. Breast lumps: A 21 year single centre clinical and histological analysis, Nigerian journal of surgery. 2014 Jan –June. 20(1) 38-41.
28. Shashikumar HB, Hameed FS. The study of correlation of estrogen receptor, progesterone receptor, and HER2 receptor status in breast cancer and its incidence in a tertiary center hospital in south India. Asian Journal of Medical Sciences. 2022 Jul 1;13(7).
29. Patnayak R, Jena A, Rukmangadha N, Chowhan AK, Sambasivaiah K, Venkatesh B, et al. Hormone receptor status (estrogen receptor, progesterone receptor), human epidermal growth factor-2 and p53 in South Indian breast cancer patients: A tertiary care center experience. Indian J Med Paediatr Oncol.2015;36(2):117-122.